

CHAPTER 4

RECONSTRUCTION OF AND PROBLEMS WITH THE URETHRA

Section 4.1: New urethra made from the anterior vaginal wall during VVF repair
Section 4.2: New urethra made from anterior bladder during VVF repair
Section 4.3: Lengthening the urethra from the anterior vaginal wall without (or following) a VVF repair
Section 4.4: Fistulas distal to the urethral orifice
Section 4.5: Managing the torn urethra and urethral strictures due to non-obstetric trauma

- When a urethra has been destroyed, or when only a small part of it remains, a new urethra can be made. This can be done by utilizing either the anterior vaginal wall or the bladder wall. The aim is to create a narrow tube which can then be compressed by surrounding tissues or a sling. However, it is difficult to re-create a functioning sphincter so the result may be a functionless tube.
- The common situations requiring urethral re-construction are:

<i>Where there is a large VVF and no urethra remains.</i>	The new urethra is made either from the vagina (section 4.1) or from the bladder (section 4.2).
<i>Where the VVF has been closed (or is small and distal) but there is a very short or no urethra.</i>	This most commonly only occurs following a VVF repair. It may also occur before any surgery when the main site of injury is the urethra rather than the bladder. Fig. 4.1b would be a good example of this type. Other causes are sometimes seen e.g. previous excision of a tumour or trauma to the urethra. The new urethra is made from the vagina (section 4.3) by treating the urethral opening (or bladder opening if the urethra is completely absent) like a fistula.
<i>If the urethra is very short before a VVF repair:</i>	<ul style="list-style-type: none"> • It can be lengthened by using the retracted urethral tissue as it is often torn in the midline. See pages 38 + 46 and Fig. 2.19m. This is relatively simple to do where it is possible. • It can be lengthened using a bladder flap as in Fig. 4.9 a + b below.

(4.1) NEW URETHRA MADE FROM THE ANTERIOR VAGINAL WALL DURING VVF REPAIR

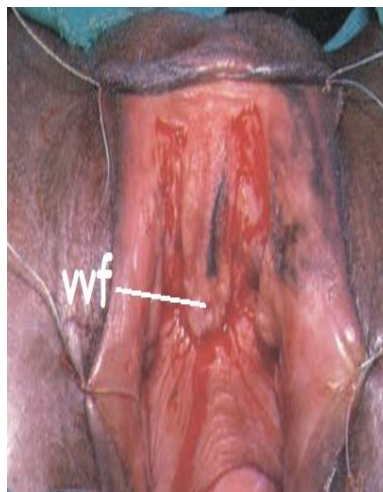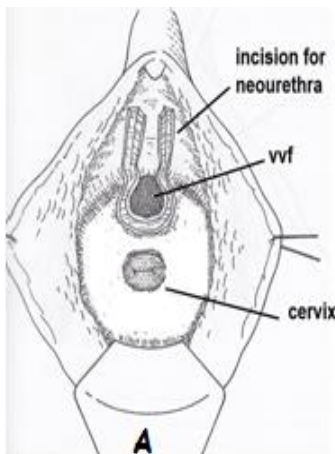


Fig. 4.1a: This diagram shows the incision around the fistula and the two incisions for the new urethra. Note there are no lateral extensions.

Fig. 4.1b: Photograph shows the U-shaped incision for the new urethra. In this case, the VVF is small so the case is similar to those described in section 4.3 (Courtesy of Kees Waaldijk). Once the incision is made, the lateral margins of the incision are undermined and mobilized.

This method uses vagina (base of original urethra) to make the urethra. It is particularly good if the tissue where the urethra should be is substantial i.e. it feels like the base of a split open urethra. If it just looks like skin, and bone is easily palpated underneath, this method is less useful.

(1) Incision

Make incision as in Fig. 4.1a around the bladder defect and then make two incisions for the new urethra. It is important to note that you avoid making the usual lateral extensions.

Incisions for the new urethra: If the incisions are not wide enough apart, failure is guaranteed. Therefore, plan your incisions carefully before you make them. Two vertical incisions are made 2.5 - 3 cm apart along the anterior vaginal wall. The length will depend on the anatomy of the particular case although 3 cm is usually sufficient.

- Do not make a new urethra too long, as this increases the risk of developing a stricture.
- As a rough guide, the new orifice ends up 2-3 cm below the clitoris.

(2) Dissection

Bladder: This is performed as described in section 2.3. In most cases, this will require a full circumferential dissection.

! Tip! Once the ureteric catheters are inserted, they can be fixed with a stitch to the suprapubic skin and lie in the floor of the new urethra. The new urethra will be stitched over them later. This keeps the catheters out of your way once they are inserted, rather than waiting until the closure of the urethra.

Urethra: Having made the two vertical incisions, dissect underneath medially for about 0.5 cm. Start a bit deep to the line of incision so the urethral wall will be thick. This dissection can be done with scissors.

Then dissect lateral to each incision as this will help to free the new urethra. You usually have to dissect deeply on each side so that the urethra is mobilized completely to the inferior pubic ramus to facilitate closure in a tension-free fashion. Often the retropubic space is entered on each side to facilitate mobilization of the urethra, urethro-vesical junction and the distal bladder.

(3) Start the closure of the bladder and urethra

Either the bladder or the neourethra closure can be started first. In most cases, start with the bladder closure (especially laterally) but it is a good idea to start closing the urethra early so that you can see what para-urethral tissues are available for closing the bladder.

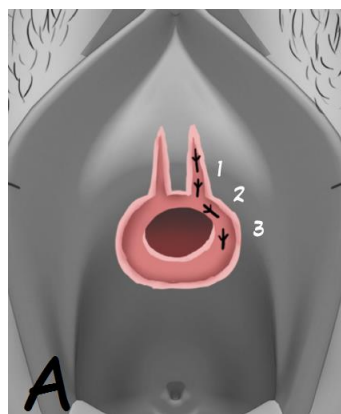


Fig. 4.2A: Shows the bites of the angle suture (1, 2, and 3) for closing the bladder.

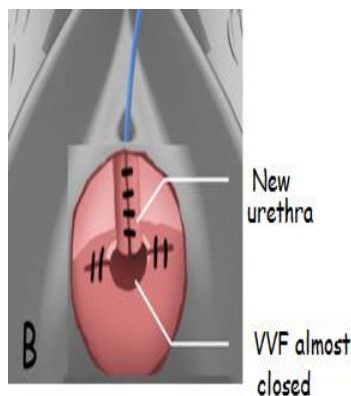


Fig. 4.2B: Shows the closed urethra about to be joined to the almost closed bladder.

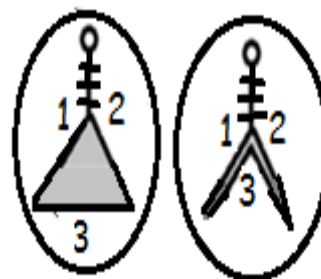


Fig. 4.2C: In this case, the new urethra is joined to the (open) bladder with a triangular stitch.

Bladder: There are several ways in which the bladder may be closed:

- (a) (Fig. 4.2A+B): Do the usual transverse closure of the bladder by stitching the lateral bladder to the bone and para-urethral tissues. The aim is to close most of the bladder first, with the exception of the central portion which will be re-connected to the new urethra. Most of the distal lateral bites (through the periosteum and para-urethral tissue) are taken in the line of the incision that you have made for the new urethra (Fig. 4.2A). Several sutures can be placed along almost the same line although Fig. 4.2A only shows one suture. However, these may reduce your access on each side when closing the urethra.

- (b) (Fig. 4.2C): If you form the new urethra first, then use a triangular stitch to join the urethra to the bladder which is not yet even partially closed. This results in the formation of two legs which are then closed. See Fig. 2.19m + n for more details.
- (c) (Fig. 2.19i): Reduce the size of the bladder by starting the closure with two legs. Then continue to reduce the bladder opening until it is small enough to join to the urethra.

Urethra:

- Put the distal suture in first, at the external urethral meatus which now holds the Foley catheter in place. With the Foley catheter in place as a guide, check after each suture that you have not caught it with a suture.
- Hold the two edges of the urethra with Allis or dissecting forceps and remove these forceps as you tie the stitch. Use interrupted 3/0 or 4/0 Vicryl or chromic catgut (Fig. 4.3).
- If the edges of the urethra do not come together without tension, you have to mobilize more on both sides by deepening the two vertical incisions.


	<p>It is important not to try to force a large catheter through a new urethra as this would increase the risk of breakdown. There is no problem using a size 14F Foley. The fit of the catheter in the urethra should not be tight as this may compromise healing due to excessive tension at the repair site. A Nelaton catheter is a useful option in this situation as this allows a 14 F to be inserted with a low risk of blockage (See Appendix 5).</p>
---	---

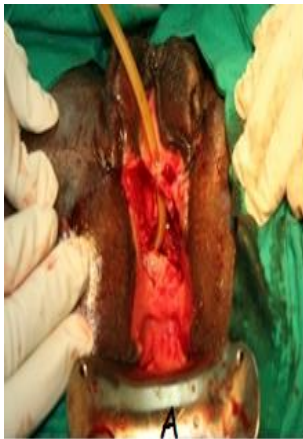

Fig. 4.3: A shows the new urethra being formed starting distally. This is then continued proximally as in B.

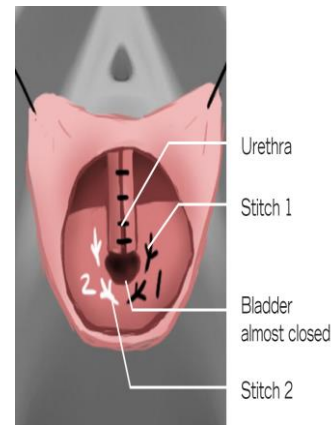
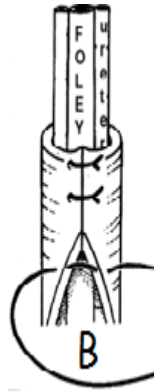

Fig. 4.4a: Closing the junction of the urethra to the bladder. Stitch 1 is shown in black and stitch 2 in white.

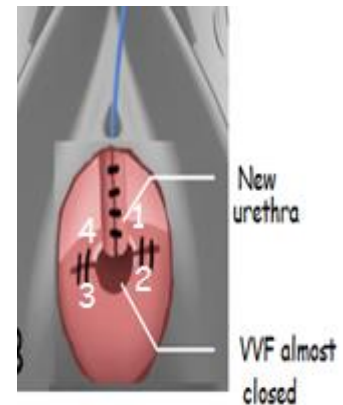


Fig. 4.4b: This shows a mattress suture (1,2,3,4) being used to join the urethra to the bladder.

(4) Connect the urethra to the bladder:

- If most of the bladder is already closed, then either:
 - The simplest is to use a mattress as in Fig. 4.4b. If there are still gaps on either side, fill them in with simple interrupted sutures.
 - Use two separate sutures as in Fig. 4.4a. For both stitch 1 and 2: One bite is along the side of the urethra. It does not enter the urethral lumen. Another bite is along the central part of the (almost closed) bladder edge.
- Another option is to join the urethra to the bladder as in Fig. 4.2C i.e. before you close the bladder. Check with dye to ensure the closure is watertight. Make sure you reinforce the junction of bladder and urethra well, as this is often where breakdown occurs. (This is popularly known as the crying corner because you and the patient will cry when it leaks here!) Do this by repeating the junction stitch but taking very superficial bites.

(5) Intermediate layer:

Once the urethra is closed, in some cases, another layer can be made from the more superficial lateral tissue which is just under the perineal skin. The skin lateral to the urethral incisions has to be undermined well to provide access to this para-urethral fibromuscular tissue (bulbocavernosus).

! Tip! When taking bites of the intermediate layer, if you go too deep or lateral, you will end up in the periosteum. This can reduce the mobility of the tissues, leading to difficulty in bringing the two edges together. It is better to work slightly more superficial.

(6) Closure of the vagina over the repair

While the bladder may heal without skin cover, the urethra rarely does.

- (a) Use the surrounding skin: You may need to mobilize the vagina off from the lateral walls more extensively and then swing in the flaps towards the midline to close. See Labial flap chapter 8.
- (b) It is strongly recommended to make a Singapore skin flap (Fig. 4.5b) to cover the anterior vagina in these cases as there is always a deficiency in the skin. Any tension in closing the vagina will only lead to breakdown of the repair.

Irrespective of what skin you use to cover the urethra, distally stitch the new external meatus to the surrounding skin with a single everting stitch (Fig. 4.5a).

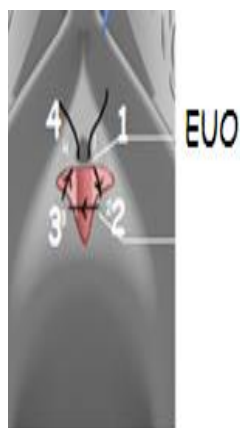

Fig. 4.5a: Shows the everting stitch to close the urethral meatus and to prevent meatal strictures.

- First bite: start inside the lumen of urethra and come out.
- Second bite: the skin from into out as shown.
- Third bite: skin on the other side from out to in.
- Fourth bite: goes back into the urethral lumen.

The two ends (1 and 4) are then tied together so the knot ends up inside the lumen. This may cause problems initially if she needs to do self-catheterization or use a plug.

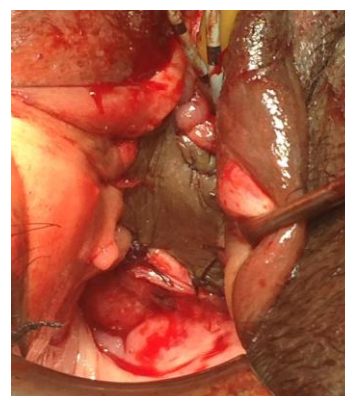


Fig 4.5b: Shows a Singapore flap used to cover the neourethra/ VVF repair.

(4.2) NEW URETHRA MADE FROM ANTERIOR BLADDER DURING VVF REPAIR

Overview of the procedure:

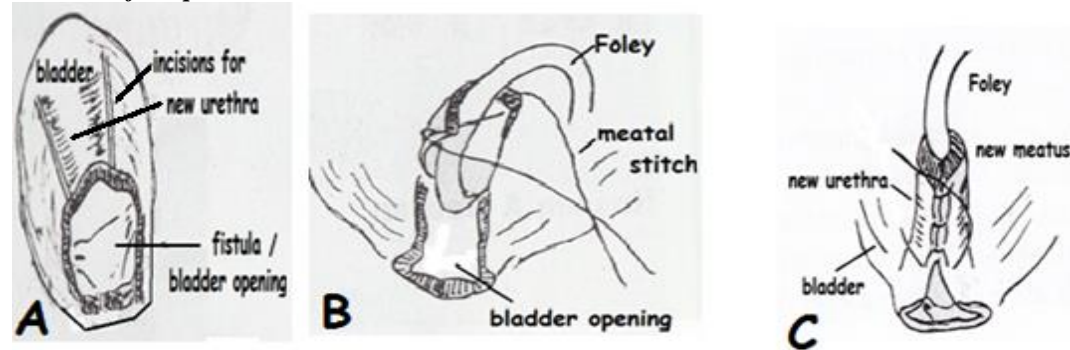
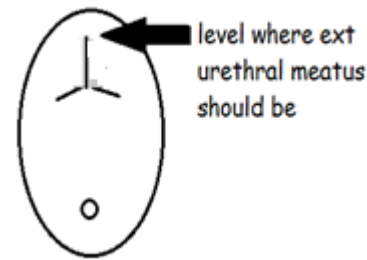


Fig. 4.6: Gives an overview of the operation. It shows the new urethra being formed from the anterior bladder. A: Two incisions are made. B: The meatal stitch is inserted around the catheter. C: The new urethra is closed. Note in this diagram the incisions are made before the meatal stitch, although it is easier to place the meatal stitch first and then make the incisions.


1. Prepare the urethral bed: Make a midline vaginal incision 2-3 cm long (Fig. 4.7a) where the urethra should be and extend this incision laterally and proximally on each side to form a triangular vaginal flap on each side. Stitch back these flaps laterally to aid exposure. These vaginal skin flaps can be used later to provide skin cover over the new urethra.

2. *Fix the bladder down:* The bladder must be stitched to the urethral bed. This is similar to the anterior layer of a circumferential repair.
 - The stitch path is from skin to periosteum and then bladder.
 - Place the first stitch at 12 o'clock going from skin and bony tissue over the former site of the urethra, and then to the anterior (distal) edge of the bladder i.e. to where the external urethral meatus should (and will) be.
 - Two more stitches are placed at 11 and 1 o'clock.

Fig. 4.7a: Shows the incision made to reflect the vaginal skin on each side. One flap is formed on each side.



3. *Form the meatus:*
 - Place the tip of a metal catheter into the bladder at 12 o'clock.
 - A transverse bite is taken on either side of (below) the catheter to bring the anterior bladder edges together and form the new external urethral orifice.
 - Keep the metal catheter in while placing the first stitch and then replace it with a Foley catheter before you tie the first stitch (Fig. 4.6B).
4. *Incise:* Make a vertical incision (Fig 4.6A) 2-3 cm into the bladder on either side of the midline which should be 3-4 cm apart or 1.5 cm on either side of the meatal stitch. The purpose of these incisions (when stitched together Fig. 4.6 C) is to narrow the bladder and form a narrow tube i.e. new urethra.

	The most common mistake in creating the new urethra is to not make the incisions far enough lateral to the midline. Remember, the new urethra has to wrap around a catheter in its full length without tension.
---	---

5. *Close urethra:* The new urethra is closed with a fine absorbable 3/0 suture. Stitch the urethra side to side (Fig 4.6C), taking good bites which makes the neo-urethra narrow.
6. *Close bladder:* The bladder is closed in whatever way it comes together easily which is usually longitudinally (Fig. 4.7b-D) but sometimes transversely (Fig. 4.7b-E). Sometimes it will close better with a legs closure (see section 2.4).

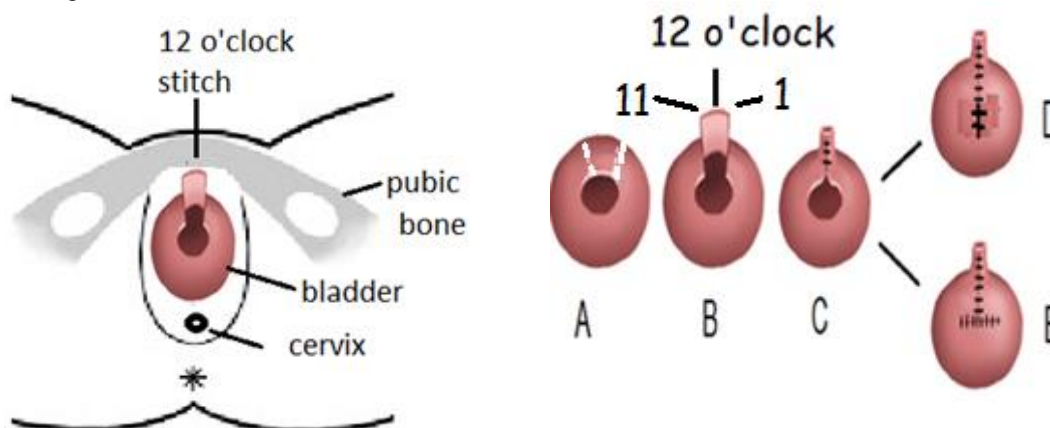


Fig. 4.7b: Shows how a tube is made from the anterior bladder and formed into a neo-urethra. In the diagram on the left, the position of the stitch at 12 o'clock which goes from the periosteum into the anterior bladder is marked on the periosteum. The 11 and 1 o'clock stitches are marked on the bladder only in B. In A: the incisions in the bladder are outlined. In B, the flap is being stitched back to form the anterior wall of the neo-urethra. In C, the posterior neo-urethra is closed. In D and E, the bladder is closed.

7. *Where possible take steps to reduce the risk of stress incontinence:*
 - a. Consider doing a pubo-coccygeal sling as described in section 1.4b.

- b. Some surgeons re-suspend the new urethra back behind the pubic symphysis with a separate stitch on each side (Fig. 4.8). With a PDS or Vicryl suture, take a bite of the periosteum and then take a bite of tissue on the side of the new urethra and tie it (see also Fig. 6.4). This is only possible if there is (pubo-cervical) fascia which is plicated across the midline and then fixed to the periosteum.

- c. Some surgeons place a Martius graft over the repair which may allow for a sling later.
8. *Fix the meatus:* The new meatus is sutured to the skin so that it does not retract.

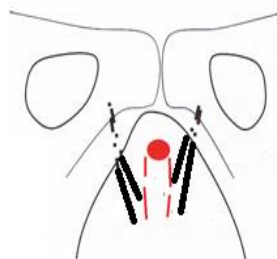


Fig. 4.8: Re-suspension of the new urethra to pubic symphysis.

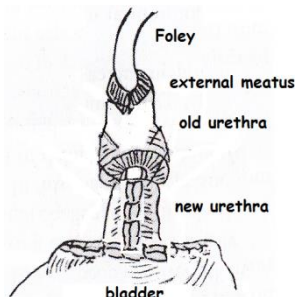
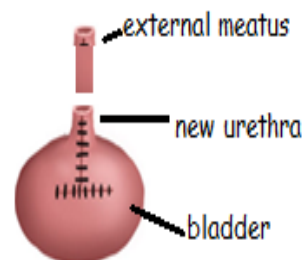


Fig. 4.9 a + b: Show the new meatus being joined to an old short urethra.



To lengthen a very short urethra: (see Fig. 4.9 a + b) If you make a new urethra to join to a very short urethra, you do an “end-to-end” anastomosis of the new urethra with the old.

- *Anterior layer:* Fix the bladder to just proximal to the short urethra with stitches at 12, 11 and 1 o’ clock. It is a good idea to also place the 10 and 2 o’clock stitches as these will be difficult to place later. Note that these are the same steps as when doing the anterior layer of a circumferential repair.
- Now place the “meatal” stitch and make the incisions to form the urethra as described above.
- *Posterior layer:* Place several interrupted sutures to join the new urethra to the old.

(4.3) LENGTHENING A SHORT URETHRA FROM THE ANTERIOR VAGINAL WALL WITHOUT (OR FOLLOWING) VVF REPAIR

In cases where there is a very short or no urethra, a new urethra can be made from the vagina by treating the old urethral/ bladder opening like a fistula. The technique is similar to that described in section 4.1.

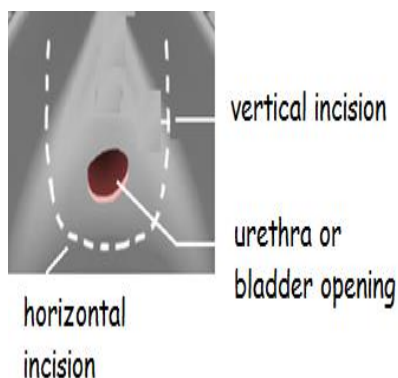


Fig. 4.10a: Shows the U incision in the vagina for forming a new urethra.

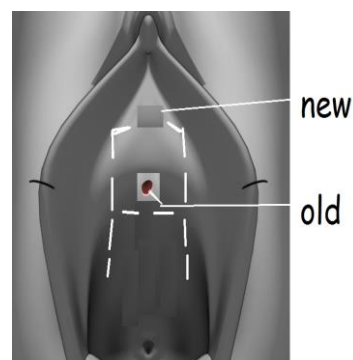
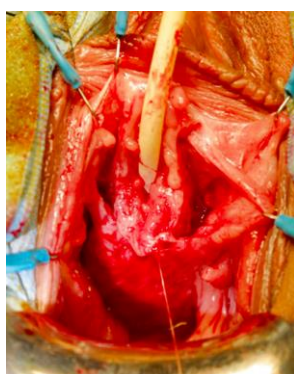


Fig. 4.10b: This shows an alternative H incision.

(1) Incision: Either a U (Fig. 4.10a) or H (Fig. 4.10b) incision can be made.

Horizontal incision: The success of this operation is dependent on the first incision, which is a horizontal/transverse proximal one. If this incision is not 2.5-3 cm wide the risk of failure is very high. The incision is placed just below the external urethral orifice (EUO) or if you are incorporating a small fistula (see Fig. 4.11)

it should be just below the fistula. Do not worry about the incisions being far away from the edge of the urethra/fistula at the sides. It is only necessary to be close in the midline proximally.

Vertical incision: (deep and lateral) Two vertical incisions are made, ensuring that they are not too distal (3 cm is typically sufficient). The incision should not extend further than the anterior edge of where the EUO should be. Cut deep into the tissue which often results in bleeding, that may need to be sutured.

In the H incision (Fig. 4.10b), the distal part (above the horizontal incision) allows the urethra to be reconstructed. The proximal part (below the horizontal incision) when mobilized, will free a flap of vagina which can be advanced distally to cover over the urethra (see Fig. 4.10 h+ i). However, it is still easy to form an advancement flap with the U incision.

(2) **Dissection:** Start the dissection at the transverse incision (proximally).

Hold an Allis forceps on either side of this incision. Be careful as you dissect in order to avoid entering the bladder, as often there has been a previous fistula repair. The general rule is to stay close to the vaginal skin, as it is better to make a hole in the vagina than a hole in the bladder. The vertical incisions are dissected as described in section 4.1.

! Tip! When separating the vagina from the bladder, to avoid button-holes, you should pull upwards (distally) rather than backwards (towards yourself) on the vagina.

(3) **Closure of the urethra:**

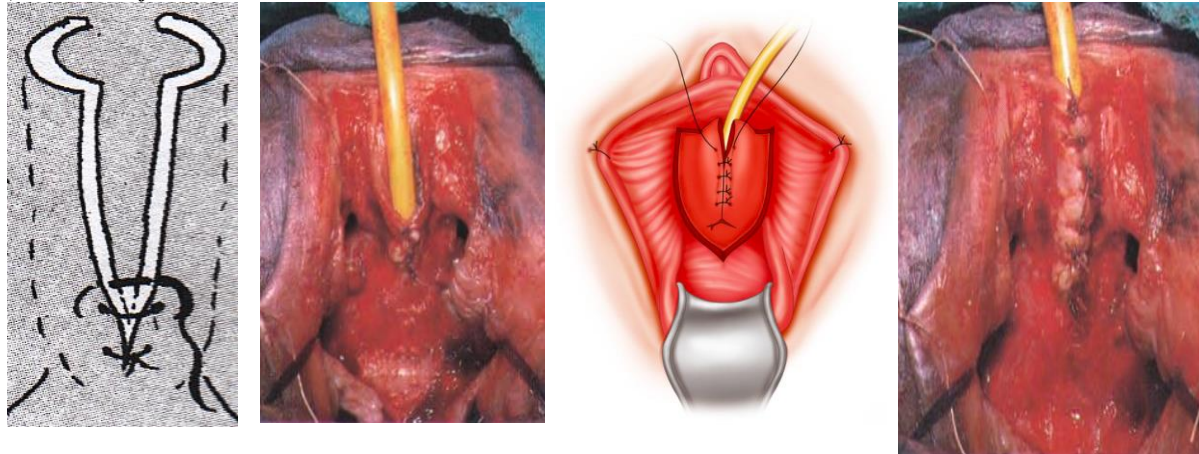


Fig. 4.10c: Shows the closure being started proximally. Courtesy of Sayeba Akhter.

Fig. 4.10d: Shows the closure completed. Photographs courtesy of Kees Waaldijk.

The difficult part is the proximal angle. This is done as a single angle stitch taking three bites (Fig. 4.10e).

- Once the proximal angle is closed, the rest of the urethra is closed side to side (longitudinally) working from proximal to distal. These sutures are placed transversely or obliquely (Fig. 4.10 c+d).
- Check as you place each suture that there is no mucosa or tissue protruding out between sutures. This is best done by getting your assistant to hold up the tied suture before you cut it.
- Also, check with a Hegar 8 or a narrow metal catheter that the urethra is patent after each suture. Alternatively, you may keep a narrow metal catheter in place until the whole urethra is reformed and then replace it with a Foley catheter. Usually, only one layer closure is possible.

(4) **Re-fixation of the fascia:**

Once the urethra is closed, look for the pubo-cervical fascia in the proximal flap in front of the cervix (see Fig. 4.10f). If it is present, then re-attach this fascia to the pubic bone with two sutures on each side (see Fig. 4.10g). The re-attachment of the fascia is critical to making the patient continent as it compresses the neourethra. In cases of VVF where the urethra is absent, this fascia is often absent.

- 1st suture (Para-urethral): this is placed at about 10 and 2 o'clock on the pubic arch.
- 2nd suture (Para-meatal): this is placed at about 11 and 1 o'clock on the pubic arch. Go from the periosteum just lateral to urethra down to take a bit of the fascia. This suture often covers over the urethral repair. Small transverse incisions can be made into the periosteum to help the fascia stay attached long-term.

(5) Closure of the vagina:

Either use a Singapore flap as described in Section 8.1 or use the vaginal advancement flap to come up and cover the urethra (Fig. 4.10h).

- If the skin is deficient, a Singapore flap is useful. It has the advantage of encouraging healing.
- If there is sufficient skin i.e. you are using an advancement flap, place (but do not tie):
 - Two medial sutures which are from the distal edge (apex) of the flap to the meatus on either side. These are marked 1 and 2 in Fig. 4.10i.
 - Two lateral stitches: these go from the skin distally, then bite the periosteum, then some pubo-cervical fascia and then the edge of the flap laterally near the cervix. These are marked 3 and 4 in Fig. 4.10i. The deep bites are taken to avoid tearing of the vagina. You mattress these sutures so go back up to the distal vagina and tie.

Note: While a bladder repair may heal without skin cover, a urethral repair does not.

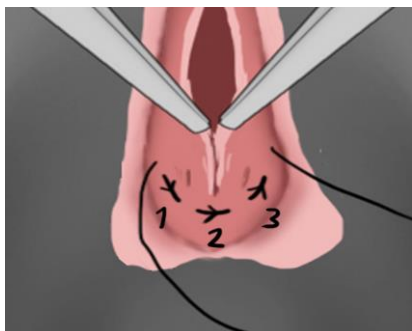


Fig. 4.10e: When closing the proximal corner, pick up the tissue in the midline (2) to prevent strictures developing. Get your assistant to hold each corner (1 and 3) with pickups. Then as you tie, the assistant can push these two corners inwards.

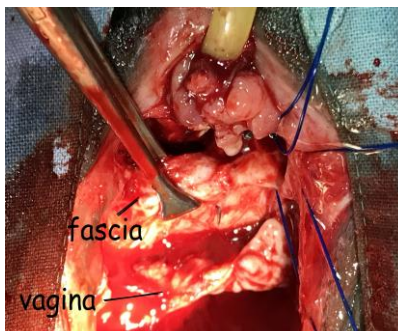


Fig. 4.10f: Shows the pubo-cervical fascia (held in Allis forceps) which is found deep to the proximal vaginal flap. It is about to be re-attached to the pubic bone anteriorly. In cases where the main injury is to the urethra, the fascia is usually well preserved as seen here.

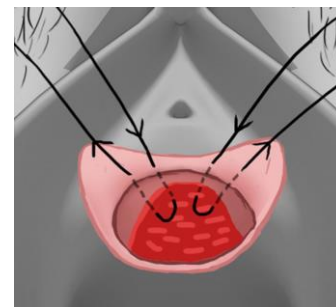


Fig. 4.10g: Shows the reattachment of the fascia to the periosteum. This adapts the posterior urethral wall to the anterior urethral wall which is critical for continence.

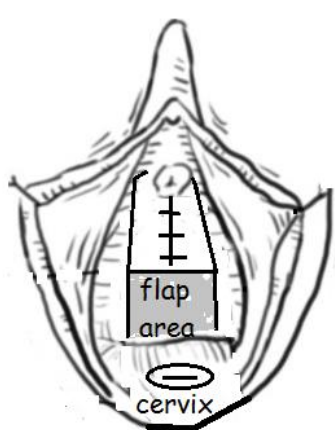


Fig. 4.10h

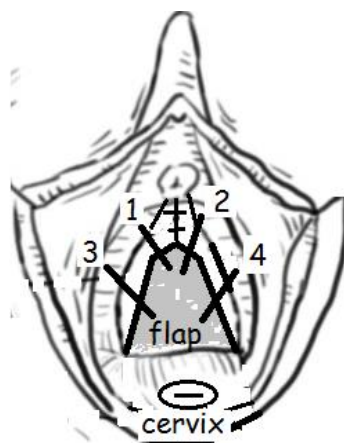


Fig. 4.10i

Vaginal advancement flap:

Fig. 4.10h: Shows the shaded area of vaginal skin before it is advanced distally to cover over the urethra.

Fig. 4.10i: Shows the flap now advanced to cover the new urethra. Two sutures are inserted on each side = 1,2,3,4. As long as the ratio of the base to the length is 1:2-3 then the flap will be viable.

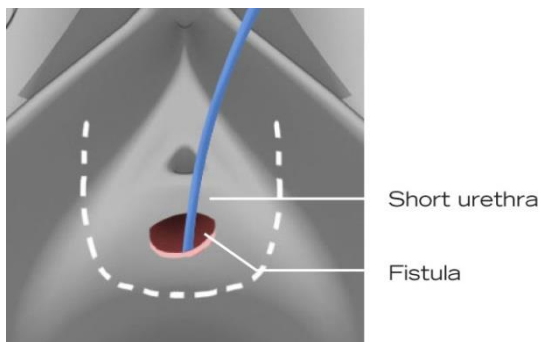
Summary of making a new urethra:

- Form the new urethra. Then where possible the para-urethral tissue is sutured as a 2nd layer over the urethra by approximating it in the midline. It is not always possible to get this second layer.
- If present, re-attach the pubo-cervical fascia to the periosteum.
- Vagina: either use an advancement flap (Fig. 4.10i) or bring in a Singapore flap (section 8.1).

! Top Tip! A firm (Nelaton) catheter without a balloon can be used when you have re-constructed the urethra. As there is no balloon channel, it allows a wider diameter for urine to drain and so it is much less likely to get blocked. Also, because it is firmer, it is easier to insert. However, it needs to be secured carefully with a suture just above the urethral meatus to prevent it falling out. (See also Appendix 5.)

Post-operative care after creation of neo-urethra

- The catheter is usually left in for 10 days, which helps the new urethra to canalize. The Foley catheter acts as a stent for the new urethra as it heals. The patient may require a catheter for a longer duration if she is unable to void and presents with urinary retention. The stitches around the urethra make it too painful for the patient to learn self-catheterization.
- If you have made a new urethra and the catheter becomes blocked post-operatively, consider inserting a supra-pubic catheter instead of removing the urethral catheter, as any urethral trauma may jeopardize your repair.



If there is a fistula close to a very short urethra:
In some cases, there is just a rim or bridge of urethra remaining distal to the fistula as in Fig. 4.11. In such cases, a good option is to incorporate the fistula into a new urethra i.e. you do not close the VVF directly but it is closed over by the formation of the new urethra.

Fig. 4.11: Shows a fistula close to a very short urethra.

(4.4) FISTULAS DISTAL TO THE URETHRAL ORIFICE

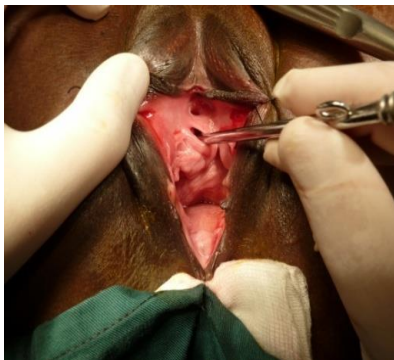


Fig. 4.12a: The metal catheter is in the normal urethral opening with the fistula seen above (distal to) it. Close up shown in Fig. 4.12b

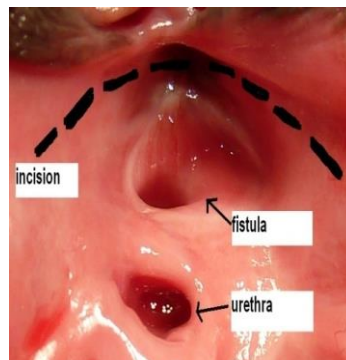


Fig. 4.12b: Shows the supra-meatal incision made to free the fistula off the pubic symphysis.

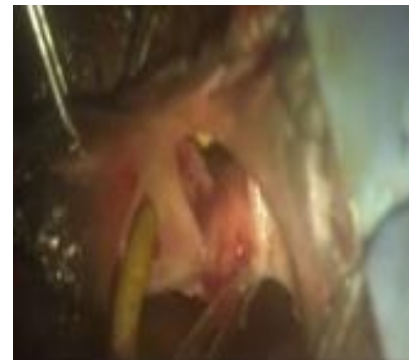


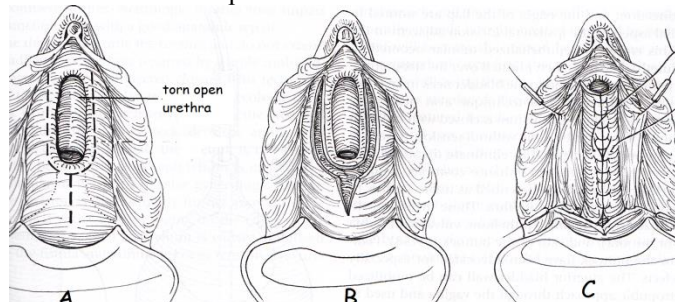
Fig. 4.13: This is another example of a post-symphysiotomy fistula to the left of the urethra. The metal catheter is in the urethra.

Occasionally you will be faced with a fistula which involves the anterior urethra. Most of these are caused by a previous symphysiotomy (Fig. 4.12 and Fig. 4.13). The approach to this type of fistula is to dissect around the fistula under the pubic arch (supra-meatal incision as shown by interrupted black line in Fig. 4.12b) similar to what is done during circumferential dissection. Once mobilized, the fistula is closed.

If during the dissection troublesome bleeding is encountered, cautery or suturing is not usually needed. All that is usually necessary is to place a gauze pack between the urethra and pubis, extending into the retropubic space for compression.

(4.5) MANAGING THE TORN URETHRA AND URETHRAL STRICTURES DUE TO NON-OBSTETRIC TRAUMA
THE TORN URETHRA

This may occur following a previous repair of a VVF or from a childbirth injury. It often seems like an 'absent urethra' on initial inspection.



The urethral bed has a red (transitional epithelium) appearance in comparison to the pink vaginal epithelium. A U-shaped incision is made, but it is at the junction of the (pink) vagina and the (red) urethra (Fig. 4.14A). The vagina at the sides is mobilized off and sutured laterally for exposure. The urethra is then closed, starting either proximally or distally and inserting a 14F Foley catheter.

Fig. 4.14: Shows a torn urethra being repaired.

URETHRAL STRICTURES DUE TO NON-OBSTETRIC TRAUMA

These cases are seen occasionally in fistula centres so it is useful to know how to manage them. Most of the ones I have seen have been caused by pelvic fractures.

Dilation: With any strictures, try dilating from below first. You need a narrow probe initially and then sequential dilators. Lubricate the dilators well before inserting. You should not push too hard as it is easy to make a false passage and then it is very difficult to find the way.

- In an adult, dilate to 16/18F in the anticipation that there will be some re-stenosis. If you only dilated to 12F it would probably narrow to an obstructive diameter fairly quickly.
- Dilation itself causes injury to the urethra resulting in a stricture so over-dilation is potentially harmful.
- Bleeding can occur without much dilation and is not a sign of over-dilation.

Suprapubic cystotomy: If you fail to dilate from below, under direct vision, make a suprapubic cystotomy and pass a sound or dilator from above down through the internal urethral opening. It helps to put a finger in the vagina from below as a guide. Alternatively, if you fail to dilate from above, you can dilate from below but put your finger into the bladder to guide the dilator up through the internal urethral opening. Then leave in a urethral and suprapubic catheter. After 7 days remove the urethral and clamp the suprapubic catheter to ensure she voids. If she voids well for two days, remove the suprapubic catheter.

Catheter post-dilation: The purpose of leaving in a catheter after dilating is not to prevent re-stenosis i.e. it will not keep the urethra open so that it heals wide. It is to reduce leakage of urine into the tissues. Therefore depending on the amount of trauma during dilation: (a) If minimal, leave the catheter in for one day (b) if a lot, leave in for three days (c) if perforation of the urethra, leave in for seven days.

Follow-up: Even if you manage to dilate the stricture, there is a high chance of recurrent stricture. An adult can do weekly self-catheterization to dilate. In a child, do it under anaesthesia after 2 months to determine how active the stricturing process is. If the urethra has not narrowed, then a longer time interval is possible and recurrent stricture is unlikely. If it is narrow again, she will need regular dilation i.e. every 3 months. Warn the patient (or her relatives) not to wait until passing urine is very difficult as the stricture will then be very tight and more difficult to dilate.

Distal stricture: Localized strictures within 5-10 mm of the meatus can be managed by circumferential excision of the distal urethra and meatus (*see Fig. 6.10c*). Then the healthy urethra is advanced and sutured circumferentially to the vaginal epithelium with interrupted sutures.

Other surgical treatment: see section 6.5.